

Case Report

Efforts to save the fetus while the mother is suffering from the psychosis: A case report study

Amirreza Ehsani¹, Maryam Bahadori², Mehdi Nikoobakht³, Seyedeh Fahimeh Shojaei^{1*}

¹Firoozgar Clinical Research and Development Center (FCRDC), Iran University of Medical Sciences, Tehran, Iran

²Department of Neurology, Firoozgar Hospital, Iran University of Medical Sciences, Tehran, Iran

³Department of Neurosurgery, Firoozgar Clinical Research and Development Center (FCRDC), Iran University of Medical Sciences, Tehran, Iran

ARTICLE INFO

Received 31 May 2018
Revised 08 July 2018
Accepted 10 July 2018
ePublish 13 July 2018
Publish 07 September 2018

Available online at:
<http://npt.tums.ac.ir>

Key words:

case report,
pregnancy,
psychotic disorders,
unsafe abortion

ABSTRACT

Background & Aim: The unsafe abortion complications may lead to mother mortality or morbidity, secondary infertility and other unwanted side effects. In some countries like ours, in many cases this kind of pregnancy termination is performed because in most cases the abortion is considered illegal by the government due to religious issues, while in some cases it may seem overly opposing the pregnancy termination. In this case report the mother was suffering from the severe psychosis symptoms, however she was not allowed to perform an abortion, and finally she decided to go to an illegal institute for abortion which results into secondary infertility. This case and similar cases bring up this question that to what extent the survival of the fetus is important in psychotic conditions of the mother.

Case Report: This study is a case report of a 32-year-old female at week 16 of pregnancy presented to the clinic with nausea and vomiting. Following to routine workup in a gynecology department she was referred to a neurologist. Therefore, after performing various imaging studies it was revealed that she had a mass in her brain and surgical resection of the mass was performed without any complication. After few days, she showed bizarre behavior and hallucination. Due to her pregnancy, the neurologists could not prescribe some medications like carbamazepine. Neurologists took the abortion into consideration, however it is illegal in our country to terminate the pregnancy after 4 months. Finally, despite her doctor's recommendation she performed abortion in an unapproved institute and returned to our clinic to follow up and continue the treatment. She is still on drugs and in the usual state.

Conclusion: Abortion within specific sort of diseases which might threaten the psychological condition of the mother and fetus should be legally permitted by the government. Therefore, by the availability of this opportunity for people who are suffering from psychological diseases like psychosis, they could easily approach to the well-known centers in order to terminate their pregnancy legally under appropriate observation. Useful studies must be done in this area to resolve the existing problem. This question should be answered by the government, health politicians, religious missionaries, clinical and social psychologists.

Introduction

Diagnosis and treatment of patients under critical condition like pregnancy and psychosis could be a struggling approach for both patients and physicians beside the unborn fetus. Ethical, legal and social consideration pertained to the rights of mother as well as the fact that there is

an evolution of the fetus at the same time together creates a challenging situation. As a matter of fact, the conflict occurs in decision making could be controversial; on one hand, the physician should pay attention to the health and life of mother and on the other hand, the fetus life is a kind of important aspect of judgment (1).

According to the court's law in Islamic Republic of Iran the fetus over 4 months is considered as an alive person, so parents are banned from terminating the pregnancy, unless

* Corresponding Author: Seyedeh Fahimeh Shojaei, Postal Address: Firoozgar Clinical Research and Development Center (FCRDC), Iran University of Medical Sciences, Tehran, Iran. Email: Shojaee.fahimeh@yahoo.com

there are specific causes of pregnancy termination such as; malformation, genomic syndromes (e.g. Down's syndrome, Patau syndrome and other genetic disorders) mentioned in constitution of Iran's law (2).

Case report

A 32-year-old pregnant woman presented to the clinic with headache, nausea, vomiting and right fascial weakness. She had two healthy children and they had no financial limitation that might affect their quality of life. Before her pregnancy, there was no sign of hallucination and psychosis.

She was presented to a physician and a complete neurological examination was done and an MRI with contrast was done to detect any possible lesion, therefore a left frontal mass measuring 3 cm in largest diameter was detected (Figure1).

On physical examination, the patient was in her usual state without any signs of psychological problem. Likewise, there was no documented drug history. In the manner corresponding to her imaging workouts the fetus demonstrated normal outcomes without any suspicious malformation or any genomic disruptions. Sonography of the patient showed an active, normal fetus in transverse position which according to the criteria estimated as a 16 weeks fetus with normal amniotic fluid and FHR equals to 180bpm. Despite her physician consult at first the patient did not visit a neurosurgeon, however, one week later, she was admitted and eventually, she was scheduled for the next available time of operation for craniotomy and excision of the tumor.

The surgery went well without any significant complication during the operation, and the histology findings showed that the mass was an old hematoma. Two weeks later,

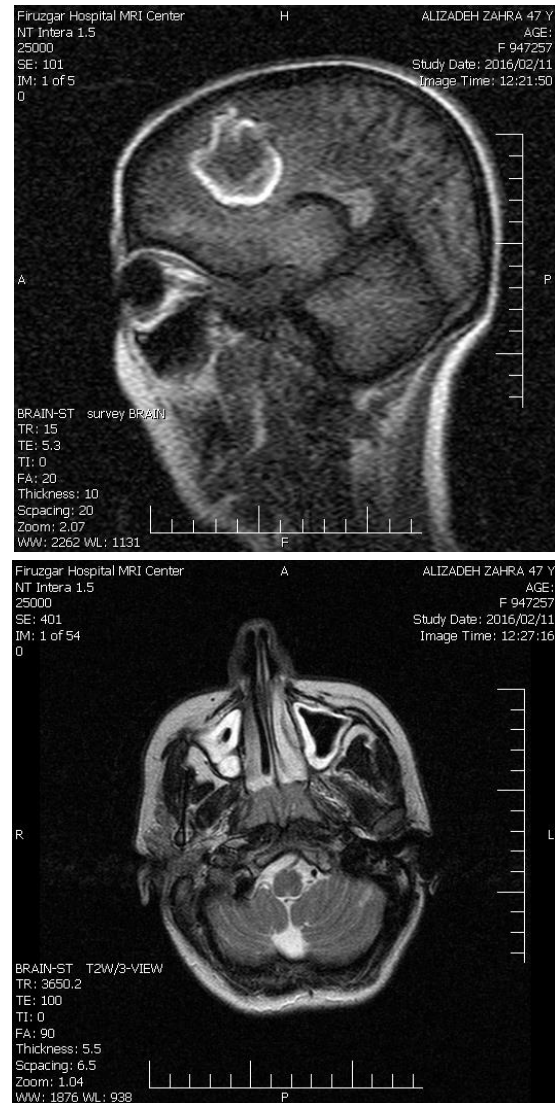


Figure 1. Brain MRI of the patient

her family stated that she had episodes of hallucination and delusion in the way that she must kiss the toilet every day in order to be forgiven by God due to her sins. Lab results like complete blood count and thyroid tests were normal.

Imaging workouts was non-specific for any known lesion to explain this condition, except a subcutaneous hematoma over the operation site. Her surgical specimen was reviewed by another pathologist and the diagnosis of the old hematoma was confirmed. Neurosurgeons considered her psychotic features as a complication of the surgery. Consequently, her

physician decided to start her on Lamotrigine, Haloperidol, and benzodiazepine so as far as medical considerations for her fetus there was no proof that these drugs are safe for the unborn fetus (3). In addition, Acyclovir was also added until the PCR result comes back negative. Her condition did not change significantly.

According to the law, she was forbidden to end her pregnancy. Her family was agitated and confused due to her severe mental condition, thus they tried to discharge their patient and eternally because of their consent and insistence she had been discharged by their own consent. Two weeks later, she came back with her family and they claimed that she had an illegal curettage at an unknown institute besides that she had not taken her medications during the time that she had been discharged and returned to the hospital. When she admitted to the hospital for the second time she received following treatment: Haloperidol, Levebel, Gabapentin, and Carbamazepine. Then all the symptoms and signs of psychosis disappeared.

After a 2-year follow-up, she was healthy and except some depression symptoms no other psychological signs and symptoms was detected. However, she has been depressed due to her illegal abortion which made her unable to have another child anymore because of the unsafe abortion complications. Because of the unsafe abortion complications, which the main ones in this patient were cervical injury and pelvic inflammatory disease (PID).

She is still on levebel daily, carbamazepine q6h and gabapentin q8h, and she is within normal condition. Now her drug's dosage has been decreased, and her treatment should be continued lifelong.

Discussion:

Based on the federal law in several countries generally there are 6 grounds which the pregnant women are allowed legally to terminate her pregnancy:

- ground 1– risk to life
- ground 2– rape or sexual abuse
- ground 3– serious fetal anomaly
- ground 4– risk to physical and sometimes mental health
- ground 5– social and economic reasons
- ground 6– on request (4).

During 2010-2014, 25% of worldwide ended pregnancies were abortion. As well as ours there are several countries in which abortion is legally prohibited by the government. The first pioneer in changing the abortion law was Soviet Union in 1920. There are many statements about abortion in different countries' laws and practically, and this would be a struggling issue for the patient-physician relationship. For instance, in the UK the abortion was criminalized in section 58 and 59 and it had been accounted as conducted offences against person's life. Under the law of Islamic Republic of Iran there are social and legal rules related to the mother and fetus, which mostly have been established according to the religious rules, and the mother cannot end the pregnancy when the fetus is aged more than 4 months, and it is permitted only when it may threaten the life of mother, otherwise there is no permission to end the pregnancy (5).

With accordance to the specific situation in Islamic Republic of Iran, the conflict between rights of mother, physician and the fetus can create a sort of challenging circumstance. During this study, the continuity of pregnancy could not be ended legally even though the mother should take her medications and it was necessary for her psychologic condition. There are particular concerns here, first the mother's condition is not feasible to keep the baby and alongside with that legally physicians are not allowed to terminate the pregnancy so she terminates her pregnancy illegally and then she took other drugs which improved her mental and physical status improved. Abortion is an emotional event that has a great impact on woman (6) and it may even lead into mother's

depression by itself (7). Massive bleeding and infection are important causes of maternal death in abortion cases (8).

Abortion complications can also increase the cost of the treatment (9). In addition, abnormal babies and premature delivery in the future pregnancies are other abortion complications (10). In some studies, it was shown that the abortion can be a cause for cancer, like breast or cervical (11, 12). Incomplete or unsterile abortion is a cause of PID (13) which is a known cause of secondary infertility, like in our case. Invasive procedures especially when they are done by inexperienced individuals can also cause several injuries in vagina, cervix, uterus, bladder, intestine, etc. in mothers (14). Abortion in the presence of the specific sort of diseases which might threaten the life or psychological condition of the mother and the fetus should be legally permitted by the government. Therefore, by the availability of this opportunity for women who are suffering from diseases like psychosis, they could easily approach to the well-known centers in order to terminate their pregnancy legally under appropriate observation. Mental health of mothers after self-termination of pregnancy is also crucial and they need emotional support thus if they proceed to a medical department and underwent suitable observation, weekly psychologist visit would help them to return to an approvable mental status and this could decrease the rate of depression following to abortion. Likewise, complications of illegal abortion in an unknown place are higher than in the legal ones and the mortality rate is significantly lower in legal institutes. It is suggested to study this challenging issue that during this situation mother's mental status and future effects of abortion should be considered or it is more important to save the baby yet the mother's mental status or even her life would be in danger under this circumstance. Psychosis is a kind of disease that can affect the behavior of

mother to the environment and baby either, so it doesn't seem wise to keep the baby inside a mother who has certain mental condition, but it is not a simple issue and there should be statistical studies on this subject to prove which one should be the priority. Sometimes mental behavior of mother can affect the fetus and mental problems could occur leading to several aspects of a society e.g. economy, quality of life and life expectancy. Finally, we should prioritize the mother condition or the health of fetus? Which one is more important considering all aspects? This question should be answered by the government, health politicians, religious missionaries, clinical and social psychologists.

Acknowledgements:

Thanks to the Firoozgar Clinical Research and Development Center (FCRDC) Iran University of Medical Sciences and the, Department of Neurosurgery Hospital Firoozgar.

Reference:

1. Patil AB, Dode P, Ahirrao A. Medical Ethics in Abortion. *Indian Journal of Clinical Practice*. 2014;25(6):544-8.
2. Aramesh K. A Shiite perspective toward abortion. *Journal of Medical Ethics and History of Medicine*. 2006(Suppl. 1):37-9.
3. Shor S, Koren G, Nulman I. Teratogenicity of lamotrigine. *Can Fam Physician*. 2007; 53(6):1007-9.
4. Berer M. Abortion law and policy around the world: in search of decriminalization. *Health and human rights*. 2017;19(1):13.
5. Hedayat KM, Shooshtarizadeh P, Raza M. Therapeutic abortion in Islam: contemporary views of Muslim Shiite scholars and effect of recent Iranian legislation. *Journal of medical ethics*. 2006;32(11):652-7.
6. Sharifi- Shaki S, Aakhte M, Alipor A, Fahimi-Far A, Taghadosi M, Karimi R, et al. The

effectiveness of mindfulness-based cognitive therapy in reducing anxiety and meta-worry in women with recurrent miscarriages. *Feyz Journal of Kashan University of Medical Sciences.* 2015; 19(4):334-40.

7. Foster DG, Steinberg JR, Roberts SC, Neuhaus J, Biggs MA. A comparison of depression and anxiety symptom trajectories between women who had an abortion and women denied one. *Psychological medicine.* 2015;45(10):2073-82.

8. Ladipo OA. Preventing and managing complications of induced abortion in Third World countries. *International Journal of Gynecology & Obstetrics.* 1989;30(Supplement):21-8.

9. Grimes DA, Benson J, Singh S, Romero M, Ganatra B, Okonofua FE, et al. Unsafe abortion: the

preventable pandemic. *The Lancet.* 2006; 368(9550):1908-19.

10. Klemetti R, Gissler M, Niinimäki M, Hemminki E. Birth outcomes after induced abortion: a nationwide register-based study of first births in Finland. *Hum Reprod.* 2012;27(11):3315-20.

11. Howe HL, SENIE RT, BZDUCH H, HERZFELD P. Early abortion and breast cancer risk among women under age 40. *International journal of epidemiology.* 1989; 18(2):300-4.

12. Scala J. Aborto: desmitificando las cifras. *La justicia uruguaya: revista jurídica.* 2007(135):31-8.

13. McGill J. A LIST OF MAJOR PHYSICAL SEQUELAE RELATED TO ABORTION.

14. Sajadi-Ernazarova KR, Martinez CL. *Abortion, Complications.* 2017.